

Biomechanical Assessment of the Anterolateral Ligament of the Knee

A Secondary Restraint in Simulated Tests of the Pivot Shift and of Anterior Stability

Ran Thein, MD, James Boorman-Padgett, BS, Kyle Stone, MS, Thomas L. Wickiewicz, MD, Carl W. Imhauser, PhD, and Andrew D. Pearle, MD

Investigation performed at the Department of Biomechanics, Hospital for Special Surgery, New York, NY

Background: Injury to the lateral capsular tissues of the knee may accompany rupture of the anterior cruciate ligament (ACL). A distinct lateral structure, the anterolateral ligament, has been identified, and reconstruction strategies for this tissue in combination with ACL reconstruction have been proposed. However, the biomechanical function of the anterolateral ligament is not well understood. Thus, this study had two research questions: (1) What is the contribution of the anterolateral ligament to knee stability in the ACL-sectioned knee? (2) Does the anterolateral ligament bear increased load in the absence of the ACL?

Methods: Twelve cadaveric knees from donors who were a mean (and standard deviation) of 43 ± 15 years old at the time of death were loaded using a robotic manipulator to simulate clinical tests of the pivot shift and anterior stability. Motions were recorded with the ACL intact, with the ACL sectioned, and with both the ACL and anterolateral ligament sectioned. In situ loads borne by the ACL and anterolateral ligament in the ACL-intact knee and borne by the anterolateral ligament in the ACL-sectioned knee were determined.

Results: Sectioning the anterolateral ligament in the ACL-sectioned knee led to mean increases of 2 to 3 mm in anterior tibial translation in both anterior stability and simulated pivot-shift tests. In the ACL-intact knee, the load borne by the anterolateral ligament was a mean of ≤ 10.2 N in response to anterior loads and < 17 N in response to the simulated pivot shift. In the ACL-sectioned knee, the load borne by the anterolateral ligament increased on average to $< 55\%$ of the load normally borne by the ACL in the intact knee. However, in the ACL-sectioned knee, the anterolateral ligament engaged only after the tibia translated beyond the physiologic limits of motion of the ACL-intact knee.

Conclusions: The anterolateral ligament is a secondary stabilizer compared with the ACL for the simulated Lachman, anterior drawer, and pivot shift examinations.

Clinical Relevance: Since the anterolateral ligament engages only during pathologic ranges of tibial translation, there is a limited need for anatomical reconstruction of the anterolateral ligament in a well-functioning ACL-reconstructed knee.

Peer Review: This article was reviewed by the Editor-in-Chief and one Deputy Editor, and it underwent blinded review by two or more outside experts. It was also reviewed by an expert in methodology and statistics. The Deputy Editor reviewed each revision of the article, and it underwent a final review by the Editor-in-Chief prior to publication. Final corrections and clarifications occurred during one or more exchanges between the author(s) and copyeditors.

Injury to the lateral capsular tissues of the knee may accompany anterior cruciate ligament (ACL) rupture in some patients¹⁻⁵. A distinct soft-tissue structure, the anterolateral ligament, has been identified within the lateral capsular envelope^{6,7}, and reconstruction strategies for this tissue in

combination with ACL reconstruction have been proposed^{8,9}. Proximally, the anterolateral ligament attaches adjacent to the lateral collateral ligament (LCL), and distally, it attaches to the proximal part of the tibia approximately halfway between Gerdy's tubercle and the fibular head^{6,7,10-12}. Although the tensile

Disclosure: This investigation was supported by the Kirby Foundation, the Clark Foundation, the Institute for Sports Medicine Research, the Surgeon in Chief Fund at the Hospital for Special Surgery, and the Gosnell Family. On the **Disclosure of Potential Conflicts of Interest** forms, which are provided with the online version of the article, one or more of the authors checked "yes" to indicate that the author had a relevant financial relationship in the biomedical arena outside the submitted work.

TABLE I Anterior Translation and Internal Rotation of the Tibia in Response to the Simulated Pivot Shift

	Intact ACL*	ACL Sectioned*	ACL and ALL Sectioned*
Anterior translation (mm)			
Flexion angle of 15°	0.1 ± 2.2 (−1.2 to 1.4)	6.8 ± 2.6† (5.3 to 8.4)	8.7 ± 3.4†‡ (6.7 to 10.7)
Flexion angle of 30°	0.7 ± 2.4 (−0.7 to 2.2)	6.9 ± 2.6† (5.3 to 8.5)	9.5 ± 3.2†‡ (7.6 to 11.4)
Internal rotation (deg)			
Flexion angle of 15°	18.6 ± 7.4 (14.3 to 23.0)	22.3 ± 6.9† (18.2 to 26.4)	24.9 ± 6.5†‡ (21.0 to 28.7)
Flexion angle of 30°	22.5 ± 9.1 (17.2 to 27.9)	25.3 ± 8.4† (20.3 to 30.2)	29.2 ± 8.0†‡ (24.4 to 33.9)

*The values are given as the mean and the standard deviation, with the 95% confidence interval in parentheses. ACL = anterior cruciate ligament, and ALL = anterolateral ligament. †The difference was significant ($p < 0.05$) relative to the ACL-intact condition. ‡The difference was significant ($p < 0.05$) relative to the ACL-sectioned condition.

properties of the anterolateral ligament have been quantified¹⁰, the in situ biomechanical function of the anterolateral ligament is not well understood.

It is known that the iliotibial band and the soft tissues comprising the midlateral capsule together resist rotational moments and anterior loads. A pioneering study by Segond revealed that the anterolateral capsular structures resist internal rotation of the tibia¹¹. Moreover, the iliotibial band and the midlateral capsule resist internal rotation and anterior translation from 30° to 90° of flexion in the ACL-sectioned knee^{13,14}.

What is not well explored, however, is the biomechanical function of the specific lateral soft tissue named the *anterolateral ligament*^{6,7}. In vitro experiments have shown that the distance between femoral and tibial insertions of the anterolateral ligament increase with internal rotation from 30° to 90° of flexion⁶. However, those in vitro data did not address whether the anterolateral ligament bears load. The anterolateral ligament provides limited resistance to anterior tibial loads in the ACL-intact knee in vitro; however, it bears about half of the applied internal rotation moment from 30° to 90° of flexion¹². Unfortunately, since the data in that experiment were expressed as percentages of the applied moment, the magnitude of force borne by the anterolateral ligament was not reported.

It has been theorized that the anterolateral ligament may be an important stabilizer against the pivot-shift phenomenon⁷, a critical predictor of instability and outcome^{15,16}. However, the role of the anterolateral ligament in resisting the complex multiplanar loads of the pivot shift has not been quantified. Therefore, the goals of this study were (1) to determine the contribution of the anterolateral ligament during knee stability testing in the setting of an ACL-sectioned knee and (2) to quantify the loads carried by the anterolateral ligament in the ACL-intact knee and in the setting of the ACL-sectioned knee during simulated clinical stability examinations.

Materials and Methods

Before biomechanical data collection was begun, 10 knees were dissected to ensure that the anterolateral ligament could be identified following previously published anatomical descriptions^{6,7}. After reflecting the iliotibial band, the tibial insertion of the anterolateral ligament was identified in all 10 knees by

flexing from 60° to 90° and applying varus and internal rotation (Fig. 1). The femoral insertion of the anterolateral ligament blended with or fanned around the femoral insertion of the LCL in most cases.

Twelve additional fresh-frozen human cadaveric knees that were not used in the anatomical study (mean age of donors at the time of death, 43 ± 15 years [range, 20 to 64 years]; 8 males and 5 right knees) were acquired. Specimens were stripped of surrounding skin and musculature except for the popliteal muscle-tendon complex, leaving all remaining ligamentous and capsular restraints intact. Then, the remaining proximal portion of the iliotibial band was dissected to within 0.5 cm of its tibial insertion.

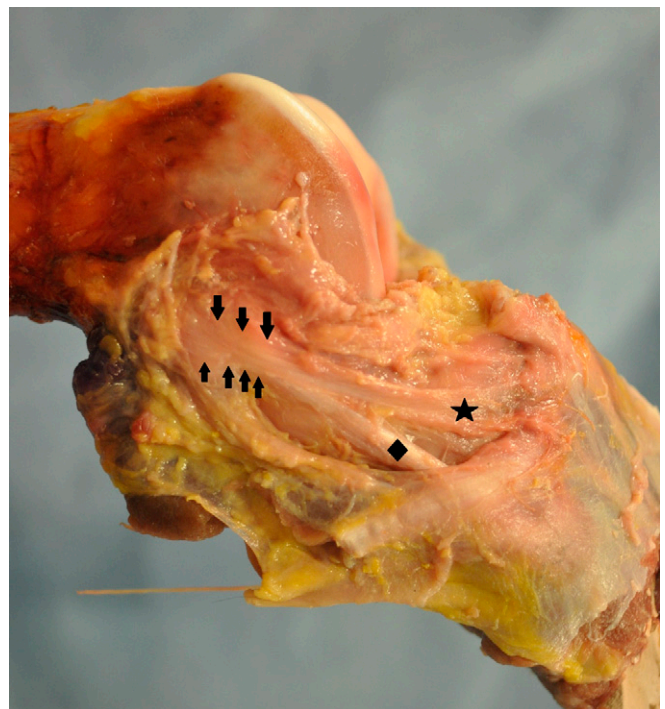


Fig. 1

Lateral view of a cadaveric knee with the anterolateral ligament isolated (star). The tibia is rotated internally and translated anteriorly to engage the lateral structures. The arrows near the femoral insertion highlight the combined, fan-like fibers of the proximal lateral collateral ligament (diamond) and anterolateral ligament.




Fig. 2
Specimens were mounted to a six-degrees-of-freedom robot instrumented with a universal force-moment sensor (arrow). The femur was fixed to the ground through the pedestal. Loads measured by the universal force-moment sensor were transformed to the anatomical coordinate system of the knee.

A medial arthrotomy was performed to confirm that the specimens were free of gross joint degeneration and ligament damage and had had no prior surgery. The femur and tibia were stripped of soft tissue to within 10 cm of the joint line and were then potted in bonding cement (Bondo; 3M). The fibula was fixed to the tibia in their anatomical orientation, using a wood screw.

Specimens were then mounted to a six-degrees-of-freedom robot (ZX165U; Kawasaki Robotics) instrumented with a universal force-moment sensor (Theta; ATI)¹⁷⁻¹⁹ (Fig. 2). The femur was fixed to the ground via a pedestal. The tibia was aligned in full extension and was mounted to a fixture attached to the end effector of the robot. Specimens were wrapped in saline solution-soaked gauze to preserve the soft tissues throughout testing.

The locations of anatomical landmarks were defined using a 3-dimensional digitizer with 0.23-mm accuracy (MicroScribe G2X; Solution Technologies). The landmarks included the femoral epicondyles, the lateralmost aspect of the distal end of the tibia approximately 25 cm distal to the joint line, the most lateral and distal portion of the sulcus on the fibula where the LCL attaches, and the midsubstance of the superficial medial collateral ligament approximately 2.5 cm distal to the medial joint line. On the basis of these anatomical landmarks, a coordinate system was defined using previously described methods^{18,20}. The long axis of the tibia defined internal and external rotation. The femoral epicondyles defined the flexion axis. The common perpendicular to both of these axes provided a reference axis for measurement of anterior-posterior translation. Tibiofemoral translations were defined relative to a point bisecting the femoral condyles¹⁸. Loads measured by the universal force-moment sensor were transformed to the anatomical coordinate system²¹.

The path of passive flexion was subsequently determined from full extension to 90° of flexion in 1° increments, using previously described

algorithms^{18,19,22}. A 10-N compressive force was applied to the tibia, while loads in the remaining directions were minimized within specified tolerances (5 N and 0.4 Nm, respectively). The knee positions along the flexion path were used as the starting points for stability testing.

A pivot-shift examination was simulated by first applying a valgus moment of 8 Nm and then applying an additional internal rotation moment of 4 Nm with the knee fixed at 15° and 30° of flexion^{18,23,24}. This 2-torque model of the pivot shift elicits anterior tibial subluxation in the ACL-sectioned knee, which is a key aspect of the clinical examination²³⁻²⁶. The Lachman and anterior drawer examinations were simulated by applying a 134-N anterior tibial load with the knee fixed at 30° and 90° of flexion, respectively. The order of stability testing was varied from knee to knee.

Before the stability testing was started, the knee was preconditioned for 10 cycles with anterior loads of 134 N at 30° of flexion and with pivoting loads at 15° of flexion¹⁸. The tests were performed in five steps (Fig. 3). (1) The kinematic trajectories for each stability test were determined with the ACL and anterolateral ligament intact. (2) Immediately before and after sectioning the ACL, the previously recorded kinematics of the intact knee were repeated and the loads at the knee were measured. (3) The net force carried by the ACL was subsequently determined using vector subtraction (i.e., the principle of superposition)¹⁷. Next, the kinematics of the ACL-sectioned knee were determined. (4) The anterolateral ligament was identified as described above and was sectioned starting at its tibial insertion. Immediately before and after sectioning the anterolateral ligament, the previously recorded kinematics of the ACL-intact and ACL-sectioned knee were repeated and the loads at the knee were measured. (5) Vector subtraction was again employed to determine the resultant force carried by the anterolateral ligament in the ACL-intact and ACL-sectioned states. Finally, stability tests were conducted in the knee lacking an ACL and an anterolateral ligament.

Kinematic outcomes were the net anterior translation of the tibia in response to the simulated Lachman, anterior drawer, and pivot shift examinations, and the net internal rotation of the tibia in response to the simulated

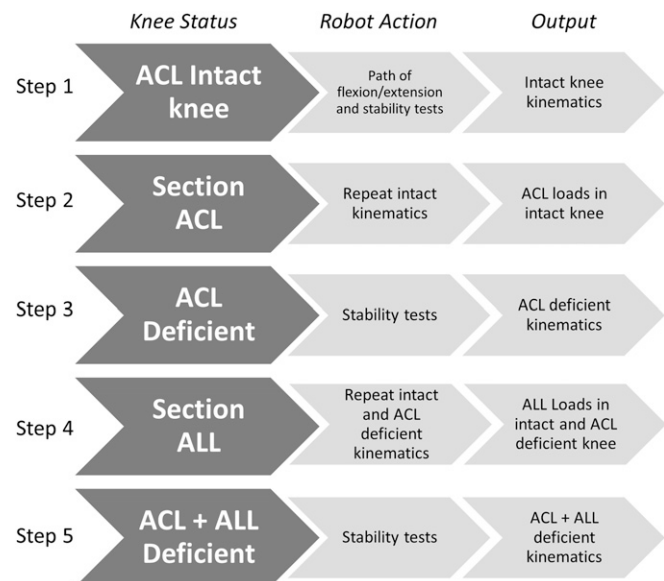


Fig. 3

Flow graph outlining the experimental protocol. Stability tests consisted of a simulated pivot-shift test, simulated Lachman test, and simulated anterior drawer test. Ligaments were sectioned in the order shown. The sequence of stability tests was varied from knee to knee within each ligament-sectioning state. ACL = anterior cruciate ligament, and ALL = anterolateral ligament.

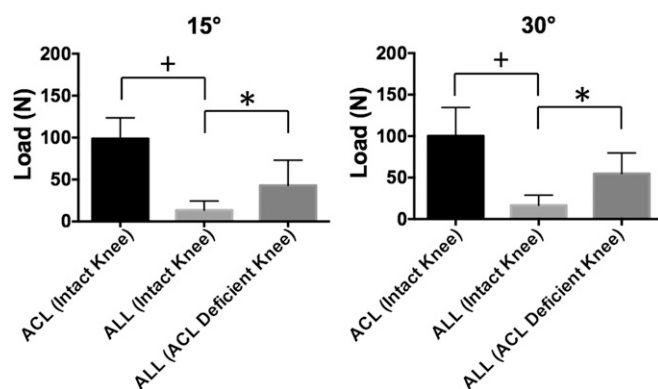


Fig. 4

Mean force carried by the anterior cruciate ligament (ACL) in the intact knee and the anterolateral ligament (ALL) in the intact and ACL-sectioned knees in response to a simulated pivot-shift examination at 15° and 30° of flexion. Error bars indicate 1 standard deviation. The plus sign indicates a significant difference between the ACL and the anterolateral ligament in the ACL-intact knee ($p < 0.05$). The asterisk indicates a significant difference between the anterolateral ligament in the intact knee and the anterolateral ligament in the ACL-sectioned knee ($p < 0.05$).

pivot shift. These outcomes were determined for the ACL-intact, ACL-sectioned, and combined ACL and anterolateral ligament-sectioned conditions. To identify differences in the kinematic data, one-way repeated-measures analysis of variance (ANOVA) with Tukey post hoc testing was performed for the ACL-intact, ACL-sectioned, and combined ACL and anterolateral ligament-sectioned conditions ($p < 0.05$). One-way repeated-measures ANOVA with Tukey post hoc testing was also used to identify differences in load borne by the ACL, and by the anterolateral ligament with an intact and a sectioned ACL ($p < 0.05$). These comparisons were performed for each stability test at each flexion angle.

Results

Kinematics

Sectioning the ACL and performing a simulated pivot-shift examination at 15° of flexion increased anterior tibial translation by a mean of 6.7 ± 1.9 mm compared with the ACL-intact knee ($p < 0.001$) (Table I) and increased internal tibial rotation by a mean of $3.7^\circ \pm 1.3^\circ$ ($p < 0.001$) (Table I). Subsequent sectioning of the anterolateral ligament resulted in a mean increase in anterior tibial translation of 1.9 ± 1.3 mm (a 27.6% increase; $p = 0.009$) and a mean increase in internal tibial rotation of $2.5^\circ \pm 1.3^\circ$ (an 11.3% increase) ($p < 0.001$) compared with isolated ACL deficiency.

Sectioning the ACL and performing a simulated pivot-shift examination at 30° of flexion increased anterior tibial translation by a mean of 6.2 ± 1.6 mm compared with the ACL-intact knee ($p < 0.001$) (Table I) and increased internal tibial rotation by a mean of $2.7^\circ \pm 1.6^\circ$ ($p < 0.001$) (Table I). Subsequent sectioning of the anterolateral ligament resulted in a mean increase in anterior tibial translation of 2.6 ± 1.1 mm (a 38.0% increase; $p < 0.001$) and a mean increase in internal tibial rotation of $3.9^\circ \pm 1.5^\circ$ (a 15.4% increase; $p < 0.001$) compared with the ACL-sectioned knee.

Sectioning the ACL increased anterior tibial translation by a mean of 12.3 ± 2.3 mm ($p < 0.001$) and 7.4 ± 4.2 mm

($p < 0.001$) compared with the ACL-intact knee during the simulated Lachman and anterior drawer examinations, respectively (Table II). Compared with the ACL-sectioned knee, subsequent sectioning of the anterolateral ligament increased anterior tibial translation by a mean of 3.1 ± 2.1 mm ($p = 0.003$) and 2.8 ± 1.3 mm ($p = 0.049$) during the simulated Lachman and anterior drawer examinations, respectively. This represents a 16.2% and 23.4% increase in anterior translation during the Lachman and anterior drawer examinations, respectively, compared with the isolated ACL-sectioned knee.

Ligament Loads

The load carried by the anterolateral ligament in the ACL-intact knee in response to a simulated pivot shift was a mean of 13.5 ± 10.8 N at 15° and 16.6 ± 12.3 N at 30° (Fig. 4). These loads correspond to 13.7% and 16.6%, respectively, of those carried by the ACL, which were 98.8 ± 24.8 N and 100.2 ± 34.3 N at 15° and 30° flexion, respectively ($p < 0.001$ for both) (Fig. 4).

The loads carried by the anterolateral ligament in the ACL-intact knee in response to the simulated Lachman and anterior drawer examinations were a mean of 10.2 ± 7.5 N and 7.2 ± 8.1 N, respectively (Fig. 5). These loads corresponded to 6.4% and 5.9%, respectively, of those carried by the ACL, which were a mean of 159.7 ± 18.5 N and 120.9 ± 16.1 N, in the simulated Lachman and anterior drawer examinations, respectively ($p < 0.001$ in both cases) (Fig. 5).

During the simulated pivot-shift examination at 15° and 30° of flexion, the loads in the anterolateral ligament after the ACL was sectioned increased to a mean of 42.9 ± 30.2 N ($p = 0.002$) and 54.7 ± 25.0 N ($p = 0.001$), respectively. The magnitude of load carried by the anterolateral ligament was 43.4%

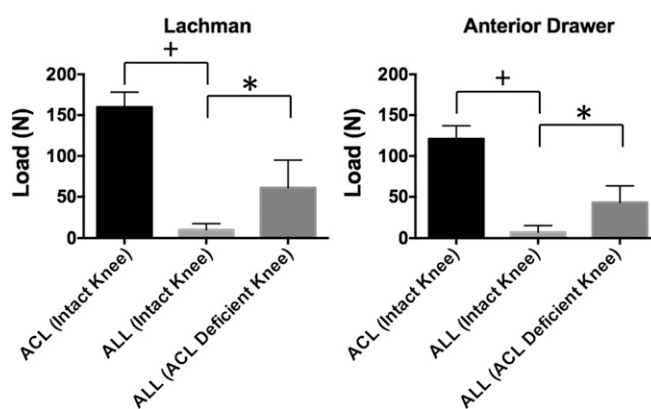


Fig. 5

Mean force carried by the anterior cruciate ligament (ACL) in the intact knee and the anterolateral ligament (ALL) in the intact and ACL-sectioned knees in response to an applied anterior load at 30° and 90° of flexion. Error bars indicate 1 standard deviation. The plus sign indicates a significant difference between the ACL and the anterolateral ligament in the ACL-intact knee ($p < 0.05$). The asterisk indicates a significant difference between the anterolateral ligament in the intact knee and the anterolateral ligament in the ACL-sectioned knee ($p < 0.05$).

TABLE II Anterior Translation of the Tibia in Response to Anterior Load During the Simulated Lachman and Anterior Drawer Examinations

Flexion Angle	Anterior Translation* (mm)		
	Intact ACL	ACL Sectioned	ACL and ALL Sectioned
30°	6.8 ± 2.2 (5.5 to 8.0)	19.1 ± 2.4† (17.6 to 20.5)	22.2 ± 3.1†‡ (20.4 to 24.0)
90°	4.7 ± 1.3 (4.0 to 5.5)	12.2 ± 4.0† (9.8 to 14.5)	15.0 ± 4.6†‡ (12.3 to 17.7)

*The values are given as the mean and the standard deviation, with the 95% confidence interval in parentheses. ACL = anterior cruciate ligament, and ALL = anterolateral ligament. †The difference was significant ($p < 0.05$) relative to the ACL-intact condition. ‡The difference was significant ($p < 0.05$) relative to the ACL-sectioned condition.

and 54.6% of that carried by the ACL in the intact knee during the pivot shift examination at 15° and 30°, respectively (Fig. 4). The increased load borne by the anterolateral ligament in the setting of the ACL-sectioned knee occurred with the tibia translated anteriorly an additional 6.7 and 6.2 mm beyond its position for the ACL-intact knee during the simulated pivot shift examination at 15° and 30°, respectively (Table I).

After the ACL was sectioned, loads carried by the anterolateral ligament increased to a mean of 61.1 ± 33.8 N in response to the simulated Lachman examination ($p < 0.001$) (Fig. 5) and increased to 43.1 ± 20.3 N in response to the anterior drawer examination ($p < 0.001$) (Fig. 5). The magnitude of load carried by the anterolateral ligament was 38.3% and 35.6% of that carried by the ACL in the intact knee during the Lachman and the anterior drawer examinations, respectively. The increased load borne by the anterolateral ligament after the ACL was sectioned occurred with the tibia translated anteriorly an additional 12.3 and 7.4 mm beyond its position for the ACL-intact knee during the Lachman and the anterior drawer examinations, respectively (Table II). During the sim-

ulated Lachman examination for the ACL-sectioned knee, the anterolateral ligament carried load as the knee translated from 12 to 20 mm (Fig. 6). In contrast, the ACL bore load as the knee translated from 3 to 7 mm anteriorly (Fig. 6).

Discussion

The most important findings were that (1) the load borne by the anterolateral ligament in the ACL-intact knee was minimal, averaging ≤ 16.6 N in response to the simulated pivot shift and ≤ 10.2 N in response to anterior loads; (2) the load borne by the anterolateral ligament increased in the ACL-sectioned knee compared with the ACL-intact knee, with an increase of nearly five to sixfold in response to isolated anterior loads and more than threefold in response to the simulated pivot shift; and (3) sectioning the anterolateral ligament in the setting of ACL insufficiency led to 2 to 3 mm of additional anterior translation in both the uniplanar anterior testing (Lachman and anterior drawer) and the multiplanar loading (simulated pivot shift).

These data suggest that the anterolateral ligament is a “secondary stabilizer” to the ACL for the pivot shift, Lachman, and anterior drawer examination. Specifically, the anterolateral ligament experiences low loads during these tests in the ACL-intact knee, but bears increased load and imparts some constraint to stability testing in the ACL-sectioned state (Figs. 4 and 5). Somewhat surprisingly, the anterolateral ligament bears increased load at the extremes of tibial translations in the ACL-sectioned knee, but fails to engage until the tibia has displaced beyond the physiologic boundaries that are present with an intact ACL (Figs. 6 and 7). For example, the tibia must translate approximately 10 to 12 mm anteriorly for the anterolateral ligament to bear at least 20 N of load during the Lachman test (Fig. 6). These data suggest that the ACL and anterolateral ligament have distinct patterns of engagement during the stability examination. The ACL is loaded as the knee is maintained within its normal, physiologic envelope of motion. In contrast, the anterolateral ligament engages only as the knee translates into a pathologic position encountered in the ACL-sectioned knee (Figs. 6 and 7). Thus, the anterolateral ligament may bear load in the setting of failed ACL reconstruction or chronic complete tears of the ACL in which patients may present with anterior tibial subluxation²⁷ of >15 mm²⁸.

Our finding that the anterolateral ligament bears minimal load in the ACL-intact knee in response to the Lachman

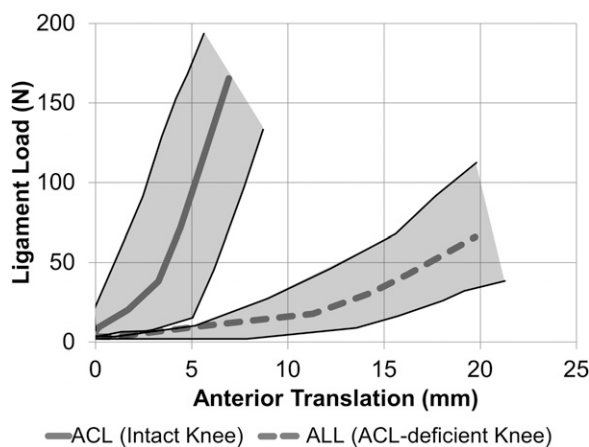


Fig. 6
Mean force carried by the anterior cruciate ligament (ACL) in the ACL-intact knee and the anterolateral ligament (ALL) in the ACL-sectioned knee as a function of anterior tibial translation during a simulated Lachman examination. The thin lines bracketing the ligament engagement paths signify the ligament load versus the anterior tibial translation of the individual specimens with the smallest and largest ligament loads.

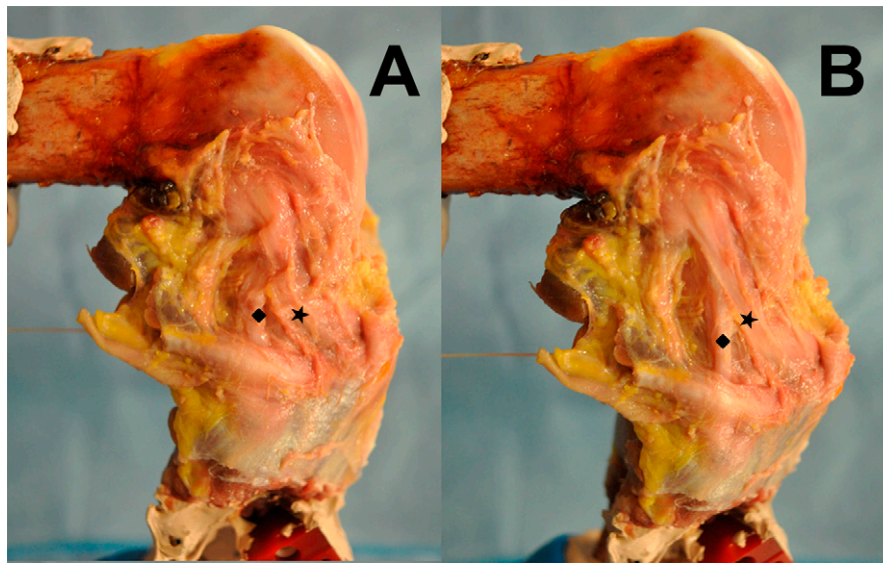


Fig. 7

Lateral view of a cadaveric knee with the anterolateral ligament (star) isolated. The femur is fixed while the tibia is manipulated manually. In **Fig. 7-A**, the tibia is held at a neutral position in 90° of flexion. In **Fig. 7-B**, the tibia is in varus and internally rotated to a subluxated position to engage the lateral soft-tissue envelope including the anterolateral ligament. The lateral collateral ligament (diamond) and anterolateral ligament appear more taut in this subluxated position.

and anterior drawer examinations corroborates previous work¹². Our finding of a tibial displacement increase of approximately 3 mm in response to anterior stability tests after anterolateral ligament sectioning agrees with a previously reported increase of 4 mm after sectioning the anterolateral structures¹³. In contrast, Spencer et al. found more muted changes in anterior translation after sectioning the anterolateral ligament in the ACL-sectioned knee, with only a 1.9-mm increase during Lachman and anterior drawer examinations; this may be due to arthritic changes noted in their older cohort of specimens or differences in the constraints of their test apparatus²⁹. The anterolateral ligament was previously found to resist isolated internal rotation moments in the ACL-intact knee at >30° of flexion, but less so at <30°¹². Similarly, our data indicate that the anterolateral ligament plays a minimal role in resisting rotatory multiplanar loads in the ACL-intact knee at 15° and 30° of flexion.

Some knees may be more dependent on the anterolateral ligament to maintain stability. One ACL-sectioned knee in our study had an increase in anterior translation of 5.5 mm and 7.2 mm during the pivot shift and Lachman examinations, respectively, after sectioning of the anterolateral ligament. This was >2.3 times the mean increase of either test. Wroble et al. also reported high interspecimen variability in the stabilizing role of the anterolateral structures¹⁴. Clinical examinations identifying individuals who are more dependent on their lateral soft tissues may help to target those who would most benefit from lateral stabilizing procedures with ACL reconstruction.

This study has limitations. First, tissues superficial to the anterolateral ligament, including the distal portion of the iliotibial band, were removed prior to testing. This portion of the iliotibial band might contribute to knee stability even though it lacked a proximal attachment. However, our measurements of

anterior tibial translation in the Lachman and anterior drawer examinations agree with previous studies in which the anterolateral tissues and iliotibial band were sectioned together^{13,14}. Therefore, this portion of the iliotibial band does not appear to play a major role. In any case, our findings are a worst-case scenario of the maximum contributions of the anterolateral ligament to knee stability, since the iliotibial band is not there to share load with it. Second, the isolated contribution of the anterolateral ligament to knee stability in an ACL-intact knee was not assessed, since anterolateral ligament injury is primarily observed in combination with ACL rupture^{1,2,11}. The order of stability testing was varied to mitigate bias caused by first sectioning the ACL and then sectioning the anterolateral ligament. Nonetheless, if repeated loading increased knee rotations and translations, our data are an upper bound of the contribution of the anterolateral ligament to knee stability. Finally, the clinical pivot-shift examination consists of applied valgus, internal rotation, and anterior loads with flexion³⁰. Although the 2-torque model of the pivot shift consists of only a subset of these loads, it causes anterior subluxation of the tibia^{23,25,26}, which is a critical aspect of the clinical pivot shift.

In conclusion, the anterolateral ligament is a secondary stabilizer to simulated pivot shift, Lachman, and anterior drawer tests. In the ACL-intact knee, the anterolateral ligament carries minimal load during these stability tests. With the ACL sectioned, the anterolateral ligament resists anterior translation and axial tibial rotation, but bears load only beyond the physiologic ranges of the ACL-intact knee. Thus, the need for anterolateral ligament reconstruction in a well-functioning ACL-reconstructed knee appears to be limited. ■

Note: The authors thank Danyal Nawabi, MD, for his insightful feedback on the manuscript.

Ran Thein, MD¹
James Boorman-Padgett, BS²
Kyle Stone, MS²
Thomas L. Wickiewicz, MD²
Carl W. Imhauser, PhD²
Andrew D. Pearle, MD²

¹Department of Orthopedic Surgery, Sheba Medical Center,
Tel-Hashomer, Israel

²Departments of Biomechanics (J.B.-P., K.S., and C.W.I.) and Orthopedic
Surgery (T.L.W. and A.D.P.), Hospital for Special Surgery, New York, NY

E-mail address for R. Thein: ranthein@gmail.com
E-mail address for J. Boorman-Padgett: BoormanPadgettJ@hss.edu
E-mail address for K. Stone: kstone3@binghamton.edu
E-mail address for T.L. Wickiewicz: WickiewiczT@hss.edu
E-mail address for C.W. Imhauser: ImhauserC@hss.edu
E-mail address for A.D. Pearle: PearleA@hss.edu

References

- Irvine GB, Dias JJ, Finlay DB. Segond fractures of the lateral tibial condyle: brief report. *J Bone Joint Surg Br.* 1987 Aug;69(4):613-4.
- Hess T, Rupp S, Hopf T, Gleitz M, Liebler J. Lateral tibial avulsion fractures and disruptions to the anterior cruciate ligament. A clinical study of their incidence and correlation. *Clin Orthop Relat Res.* 1994 Jun;303:193-7.
- Dietz GW, Wilcox DM, Montgomery JB. Segond tibial condyle fracture: lateral capsular ligament avulsion. *Radiology.* 1986 May;159(2):467-9.
- Claes S, Luyckx T, Vereecke E, Bellemans J. The Segond fracture: a bony injury of the anterolateral ligament of the knee. *Arthroscopy.* 2014 Nov;30(11):1475-82. Epub 2014 Aug 8.
- Campos JC, Chung CB, Lektrakul N, Pedowitz R, Trudell D, Yu J, Resnick D. Pathogenesis of the Segond fracture: anatomic and MR imaging evidence of an iliotibial tract or anterior oblique band avulsion. *Radiology.* 2001 May;219(2):381-6.
- Dodds AL, Halewood C, Gupta CM, Williams A, Amis AA. The anterolateral ligament: anatomy, length changes and association with the Segond fracture. *Bone Joint J.* 2014 Mar;96(3):325-31.
- Claes S, Vereecke E, Maes M, Victor J, Verdonk P, Bellemans J. Anatomy of the anterolateral ligament of the knee. *J Anat.* 2013 Oct;223(4):321-8. Epub 2013 Aug 1.
- Rezanoff AJ, Catherine S, Spencer L, Tran MN, Litchfield RB, Getgood AM. Radiographic landmarks for surgical reconstruction of the anterolateral ligament of the knee. *Knee Surg Sports Traumatol Arthrosc.* 2015 Nov;23(11):3196-201. Epub 2014 Jun 17.
- Sonnerly-Cottet B, Thauan M, Freychet B, Pupim BH, Murphy CG, Claes S. Outcome of a combined anterior cruciate ligament and anterolateral ligament reconstruction technique with a minimum 2-year follow-up. *Am J Sports Med.* 2015 Mar 4 Jul;43(7):1598-605. Epub 2015 Mar 4.
- Kennedy MI, Claes S, Fusco FA, Williams BT, Goldsmith MT, Turnbull TL, Wijdicks CA, LaPrade RF. The anterolateral ligament: an anatomic, radiographic, and biomechanical analysis. *Am J Sports Med.* 2015 Apr 17 Jul;43(7):1606-15.
- Segond P. Recherches cliniques et expérimentales sur les épanchements sanguins du genou par entorse. *Progres Med.* 1879(7):297-9, 319-21, 40-1.
- Parsons EM, Gee AO, Spiekerman C, Cavanagh PR. The biomechanical function of the anterolateral ligament of the knee. *Am J Sports Med.* 2015 Mar;43(3):669-74. Epub 2015 Jan 2.
- Samuelson M, Draganich LF, Zhou X, Krumins P, Reider B. The effects of knee reconstruction on combined anterior cruciate ligament and anterolateral capsular deficiencies. *Am J Sports Med.* 1996 Jul-Aug;24(4):492-7.
- Wroble RR, Grood ES, Cummings JS, Henderson JM, Noyes FR. The role of the lateral extraarticular restraints in the anterior cruciate ligament-deficient knee. *Am J Sports Med.* 1993 Mar-Apr;21(2):257-62; discussion 263.
- Kocher MS, Steadman JR, Briggs KK, Sterett WI, Hawkins RJ. Relationships between objective assessment of ligament stability and subjective assessment of symptoms and function after anterior cruciate ligament reconstruction. *Am J Sports Med.* 2004 Apr-May;32(3):629-34.
- Leitze Z, Losee RE, Jokl P, Johnson TR, Feagin JA. Implications of the pivot shift in the ACL-deficient knee. *Clin Orthop Relat Res.* 2005 Jul;436:229-36.
- Woo SL, Fox RJ, Sakane M, Livesay GA, Rudy TW, Fu FH. Biomechanics of the ACL: measurements of in situ force in the ACL and knee kinematics. *Knee.* 1998; 5(4):267-88.
- Imhauser C, Mauro C, Choi D, Rosenberg E, Mathew S, Nguyen J, Ma Y, Wickiewicz T. Abnormal tibiofemoral contact stress and its association with altered kinematics after center-center anterior cruciate ligament reconstruction: an in vitro study. *Am J Sports Med.* 2013 Apr;41(4):815-25. Epub 2013 Mar 7.
- Fujie H, Mabuchi K, Woo SL, Livesay GA, Arai S, Tsukamoto Y. The use of robotics technology to study human joint kinematics: a new methodology. *J Biomech Eng.* 1993 Aug;115(3):211-7.
- Grood ES, Suntay WJ. A joint coordinate system for the clinical description of three-dimensional motions: application to the knee. *J Biomech Eng.* 1983 May; 105(2):136-44.
- Yoshikawa T. Foundations of robotics analysis and control. Cambridge: MIT Press; 1990.
- Prisk VR, Imhauser CW, O'Loughlin PF, Kennedy JG. Lateral ligament repair and reconstruction restore neither contact mechanics of the ankle joint nor motion patterns of the hindfoot. *J Bone Joint Surg Am.* 2010 Oct 20;92(14):2375-86.
- Kanamori A, Zeminski J, Rudy TW, Li G, Fu FH, Woo SL. The effect of axial tibial torque on the function of the anterior cruciate ligament: a biomechanical study of a simulated pivot shift test. *Arthroscopy.* 2002 Apr;18(4):394-8.
- Kanamori A, Woo SL, Ma CB, Zeminski J, Rudy TW, Li G, Livesay GA. The forces in the anterior cruciate ligament and knee kinematics during a simulated pivot shift test: a human cadaveric study using robotic technology. *Arthroscopy.* 2000 Sep; 16(6):633-9.
- Engebretsen L, Wijdicks CA, Anderson CJ, Westerhaus B, LaPrade RF. Evaluation of a simulated pivot shift test: a biomechanical study. *Knee Surg Sports Traumatol Arthrosc.* 2012 Apr;20(4):698-702. Epub 2011 Nov 5.
- Noyes FR, Jetter AW, Grood ES, Harms SP, Gardner EJ, Levy MS. Anterior cruciate ligament function in providing rotational stability assessed by medial and lateral tibiofemoral compartment translations and subluxations. *Am J Sports Med.* 2015 Mar;43(3):683-92. Epub 2014 Dec 24.
- Almekinders LC, Pandarinath R, Rahusen FT. Knee stability following anterior cruciate ligament rupture and surgery. The contribution of irreducible tibial subluxation. *J Bone Joint Surg Am.* 2004 May;86(5):983-7.
- Tanaka MJ, Jones KJ, Gargiulo AM, Delos D, Wickiewicz TL, Potter HG, Pearle AD. Passive anterior tibial subluxation in anterior cruciate ligament-deficient knees. *Am J Sports Med.* 2013 Oct;41(10):2347-52. Epub 2013 Aug 8.
- Spencer L, Burkhart TA, Tran MN, Rezanoff AJ, Deo S, Catherine S, Getgood AM. Biomechanical analysis of simulated clinical testing and reconstruction of the anterolateral ligament of the knee. *Am J Sports Med.* 2015 Sep;43(9):2189-97. Epub 2015 Jun 19.
- Pathare NP, Nicholas SJ, Colbrunn R, McHugh MP. Kinematic analysis of the indirect femoral insertion of the anterior cruciate ligament: implications for anatomic femoral tunnel placement. *Arthroscopy.* 2014 Nov;30(11):1430-8. Epub 2014 Sep 16.